

Full-length article

Effects of resveratrol and methylprednisolone on biochemical, neurobehavioral and histopathological recovery after experimental spinal cord injury

Ozkan ATES^{1,6}, Suleyman CAYLI¹, Eyup ALTINOZ², Iclal GURSES³, Neslihan YUCEL⁴, Ayhan KOCAK¹, Saim YOLOGLU⁵, Yusuf TURKOZ²

¹Department of Neurosurgery, ²Department of Biochemistry, ³Department of Pathology, ⁴Department of Emergency Medicine, ⁵Department of Biostatistics, Inonu University, School of Medicine, 44280 Malatya, Turkey

Key words

lipid peroxidation; resveratrol; spinal cord

⁶ Correspondence to Dr Ozkan ATES.
Phn 90-42-2341-0669, ext 3208.
Fax 90-42-2341-0738.
E-mail atesozkan@hotmail.com

Received 2006-03-10
Accepted 2006-06-01

doi: 10.1111/j.1745-7254.2006.00416.x

Abstract

Aim: To investigate the neuroprotective effect of resveratrol in an experimental spinal cord injury (SCI) model in rats. **Methods:** Male Wistar albino rats weighing 200–250 g were randomized into six groups. Weight-drop trauma was performed for SCI. Group 1 underwent laminectomy alone. Group 2 underwent laminectomy followed by SCI. Groups 3, 4, 5, and 6 underwent laminectomy followed by SCI and received resveratrol (100 mg/kg), methylprednisolone (MP) (30 mg/kg), resveratrol (100 mg/kg) plus MP (30 mg/kg), and ethanol (2%), respectively. The rats were divided into two subgroups for biochemical analysis (killed at 24 h after surgery) and for neurobehavioral and histopathological evaluation (killed at 6 weeks after surgery). Posttraumatic neurological recovery after surgery was recorded weekly. **Results:** Groups 3 and 5 revealed significantly lower malondialdehyde, nitric oxide, xanthine oxidase, and higher glutathione levels than group 4 ($P < 0.05$). Neurological recovery rates were significantly better in groups 3 and 5 than group 4 ($P < 0.05$). When spinal trauma size ratios were compared, there was no significant difference between treatment groups. **Conclusion:** Resveratrol treatment revealed better biochemical recovery in the acute stage of trauma than MP treatment. Although resveratrol and combined treatment revealed better neurobehavioral recovery than MP treatment; resveratrol, MP, and combined treatment modalities improved histopathological recovery at the same level in the final stage of the experiment. Future studies involving different doses of resveratrol and different doses combinations with MP could promise better results as each drug has a different anti-oxidative mechanism of action.

Introduction

Traumatic spinal cord injury (SCI) includes primary and secondary injury mechanisms. Impact injury to the spinal cord causes mechanical damage to neuronal and vascular tissue, which is referred as primary damage^[1,2]. Many pathological changes seen after SCI include edema, electrolyte changes, loss of energy metabolism, biochemical changes, altered blood flow and changes in microvascular permeability, which could give rise to irreversible neural tissue injury^[3–8],

and are called secondary injury. Primary impact to the spinal cord causes activation of membrane phospholipases and lipases, hydrolysis of membrane phospholipids, production of biologically active eicosanoids, and peroxidation of lipids with the formation of oxygen free radicals. A lot of experimental studies have been performed to show the complex pathophysiological mechanisms of secondary injury after SCI^[9,10].

Previous experimental studies showed that methylprednisolone (MP) treatment had a beneficial effect on functional

recovery after SCI^[11–13]. Although MP treatment improves neurological recovery after experimental SCI, the underlying mechanism is not fully understood. Previous reported experimental data point to MP preventing lipid peroxidation, free radical formation and edema^[14].

Resveratrol (3, 4', 5 trihydroxystilbene) is a naturally occurring phytoalexin present in high concentrations in the skin and seeds of grapes^[15]. It occurs naturally in a trans or cis isoform of resveratrol are correct isoform^[16,17]. Several studies have shown the antioxidative effect of resveratrol via prevention of lipid peroxidation^[18,19]. Additionally, it has been reported that resveratrol has several biologic effects such as anti-platelet activity^[20], estrogenic activity^[21], anti-inflammatory activity attributed to cyclooxygenase inhibition^[22,23]. Resveratrol also stimulates nitric oxide (NO) production in endothelial cells and has a vasodilatory effect on blood vessels^[24].

The purpose of the present study was to investigate neurobehavioral and histological recovery, and evaluate biochemical responses to the treatment of experimental SCI in rats with resveratrol, MP and both resveratrol and MP.

Materials and methods

The experimental protocol was evaluated and approved by the Ethics Review Committee of Inonu University, Faculty of Medicine. Adult male Wistar albino rats weighing 200–250 g (221.5±28) and aged 14–16 weeks (15±0.9) were used in this study. The rats were housed in a temperature-controlled room (22–25 °C). Water and food were given *ad libitum*. Before surgery, all rats were tested and a normal motor function was found. The animals were anesthetized by an intraperitoneal injection of 10 mg/kg xylazine (Bayer Birlesik Alman İlaç Fabrikalari TAS, Istanbul, Turkey) and 50 mg/kg ketamine hydrochloride (Parke Davis, İstanbul, Turkey). A rectal probe was inserted and the animals were positioned on a thermistor-controlled heating pad. Under sterile surgical conditions, and following a midline skin incision at T5–12 and paravertebral muscle dissection, spinous processes and laminar arcs of T7–10 were removed with the assistance of a surgical microscope. The dura was left intact. Weight-drop trauma modeling was performed for all the animals^[25]. The animals were subjected to an impact of 50 g/cm to the dorsal surface of the spinal cord. The force was applied via a stainless steel rod (3-mm diameter tip, weighing 5 g) that was rounded at the surface. The rod was dropped vertically through a 10-cm guide tube that was positioned perpendicular to the center of the spinal cord. After the trauma, the muscles and incision were sutured with 5–0 vicryl

suture (Ethicon, Manufacturer Johnson and Johnson Intl, Lenneke Marelaan, Belgium).

Animals were randomized into six groups, each having 15 rats. Group 1 underwent laminectomy alone. Group 2 underwent laminectomy followed by SCI and received no medication. Group 3 underwent laminectomy followed by SCI and received resveratrol. Group 4 underwent laminectomy followed by SCI and received MP. Group 5 underwent laminectomy followed by SCI and received resveratrol and MP. Group 6 underwent laminectomy followed by SCI and received ethanol.

Resveratrol (Sigma Chemicals, St Louis, MO, USA) was prepared freshly by dissolving in 50% ethanol and was diluted in physiological saline (2%). A 100 mg/kg single dose of resveratrol to group 3; a 30 mg/kg single dose of MP (Mustafa Nevzat İlaç Sanayi AS) to the group 4; a 100 mg/kg single dose of resveratrol and a 30 mg/kg single dose of MP to group 5; and 1 mL ethanol (2%) to group 6 were administered intraperitoneally immediately after trauma.

Each group of rats was then subdivided into two subgroups, one of which was killed at the 24 h for biochemical analysis (6 rats in each group), and the other at the 6th week for neurobehavioral and histopathological assessment (9 rats in each group) following trauma.

All rats in the 6-week group received gentamycin twice daily during the first 3 d as prophylaxis against urinary tract infection. Bladders were emptied manually twice a day during this period. In case of mortality in any group, additional rats were assigned to ensure a minimum of six rats per each study sub-group. Post traumatic neurological recovery was recorded weekly during six weeks for the rats in the 6-week group. Either after 24 h or 6 weeks, all the animals were killed and 1-cm spinal cord samples were removed for biochemical analysis and histopathological examination of the injured spinal cord area.

Behavioral assessment

Motor function score We used a motor function scale^[26] that was a slight modification of the motor score defined by Gale *et al*^[27]. This motor function scale is scored between 0 and 6 points as follows; 0 point for if there is no movement of the hind limbs; 1 point for only perceptible movement; 2 points for only visible joint movements; 3 points for hind limb movement but can not support bodyweight; 4 points for movement with supporting bodyweight; 5 points for walking with mild deficit; 6 points for normal walking. The animals were allowed to move freely in an open field (0.7 m×0.9 m), and were observed for at least 1 min. An observer who was blinded to the groups observed and recorded the movements in the hip, knee and ankle joints.

Inclined plane score Rivlin and Tator's angle board test, which consisted of measuring the maximum angle at which an animal can support its weight on an inclined plane measured in 0 to 90 degrees, was used in this study^[28]. The animals were placed transversely on the inclined plane and the highest angle a rat could maintain for 5 s was recorded by the same blinded observer. And the highest angle for each rat was described as the capacity angle for that rat.

Histopathological assessment Six weeks after SCI, 6 rats from each group were deeply anesthetized with sodium pentobarbital, and intracardiac perfusion was performed with isotonic saline for 5 min, followed by 10% formaldehyde for 5 min. After perfusion, spinal cords were removed immediately and immersed in 10% formaldehyde for one week. The spinal cords, which contained the contusion epicenter, were embedded in paraffin. Each block was serially sectioned horizontally at 5 μ m. Sections were stained with hematoxylin and eosin (H&E). The slides were viewed under a light microscope to study the structural changes.

Quantitative histopathological evaluation of the spinal lesion was conducted for each sample by light microscopy. Photographs of spinal cord specimens were taken under microscopy, and these images were exported to a computer for analysis. The border of the lesion was drawn and the percentage of lesion areas of each sample was measured^[29] using an image analysis system (Leica Micros Imaging Solutions, Cambridge, UK).

Biochemical analysis Six rats from each group were killed for biochemical analysis 24 h after injury. The injured spinal cord samples were immediately frozen and stored in a -70 °C freezer for assays of malondialdehyde (MDA), glutathione (GSH), nitric oxide (NO) levels and xanthine oxidase activity.

Lipid peroxidation measurements The level of lipid peroxides in traumatized spinal cord tissue were measured as thiobarbituric acid-reactive material and determined using the method of Mihara and Uchiyama^[30]. MDA has been identified as the product of lipid peroxidation that reacts with thiobarbituric acid to give a red species absorbing at 535 nm. The assay procedure for lipid peroxide in spinal cord tissue was set up as follows. Tissues were homogenized in 10 volumes (*w/v*) of cold 1.5% KCl. Half a milliliter (0.5 mL) of homogenate was mixed with 3 mL of 1% H₃PO₄ and 1 mL 0.6% thiobarbituric acid. The mixture was then heated in boiling water for 60 min. After cooling, the color was extracted into 4 mL *n*-butanol and the absorbance was recorded at 535 nm and 520 nm. Using tetramethoxypropane as the standard, tissue lipid peroxidate levels were calculated as nanomole per gram of wet tissue.

Glutathione level measurements GSH levels were measured using the method of Elman^[31]. GSH reacted with 5,5-dithiobis-2-nitrobenzoic acid resulting in the formation of a product that has a maximal absorbance at 410 nm. The results are expressed as nanomoles per gram wet tissue.

Nitrite/nitrate measurements NO levels were measured as total nitrite with the spectrophotometric Greiss reaction, because total nitrite is an index of endogenous nitric oxide production^[32,33]. The procedure was partly adapted from the method described by Ozbek *et al*^[34]. Results were reported as per gram wet tissue.

Xanthine oxidase (XO) activity measurements XO activity was determined spectrophotometrically according to the method of Prajda and Weber based on the formation of uric acid from xanthine, which increases absorbance at 292 nm (ϵ_M 9.2 \times 10³)^[35]. One unit of activity was defined as 1 mmol of uric acid formed per min, and data are presented as U/mg protein.

Statistical analysis Data were analyzed using an SPSS 13.0 for Windows program on a computer. Results were expressed as mean \pm SEM. All parameters were tested with Shapiro-Wilks test, and distribution was not normal ($P > 0.05$). Therefore, comparison among groups was tested with Kruskal-Wallis test and Bonferroni Mann-Whitney U-test was used for dual comparison. $P < 0.05$ was considered statistically significant.

Results

Mortality Some rats from the 6-week group died after spinal cord injury before completion of the protocol. Three of 9 rats in group 2 (33.3%), 2 of 9 rats in group 3 (22.2%), 1 of 9 rats in group 4 (11.1%), and 2 of 9 rats in group 5 (22.2%) died within the first 2 weeks of the study. The proportions among the 6-week groups varied widely at the end of study. For equalizing the rat number in each group, 1 rat from group 3, 2 rats from group 4, 1 rat from group 5, and 3 rats from group 6 were randomly excluded from the study.

Behavioral assessment

Motor function score Trauma caused a significant impairment in motor function score as compared to the control group values (Figure 1). A significant recovery rate was observed in the rats treated with MP, resveratrol and MP+resveratrol ($P < 0.05$). When treatment groups were compared at the 6th week, resveratrol and the combined treatment group revealed a significantly higher motor improvement rate than the MP treatment group ($P < 0.05$). However there was no significant difference between the resveratrol and combined treatment group ($P > 0.05$).

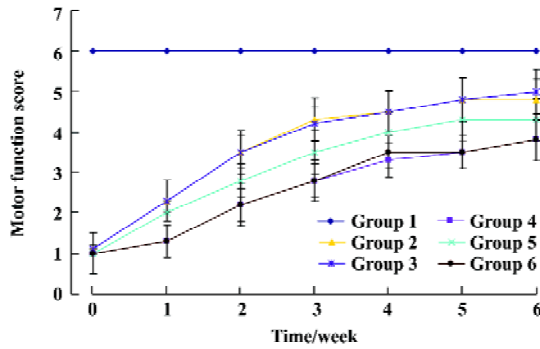


Figure 1. Motor function scores in all groups. The significant recovery rate was observed in the rats treated with resveratrol (Group 3), MP (Group 4), and MP+resveratrol (Group 5) ($P<0.05$). Groups 3 and 5 revealed a significantly higher motor improvement rate than group 4 ($P<0.05$). $n=6$. Mean \pm SEM. Group 1: Laminectomy. Group 2: Laminectomy+SCI; Group 6: Laminectomy+SCI+ethanol.

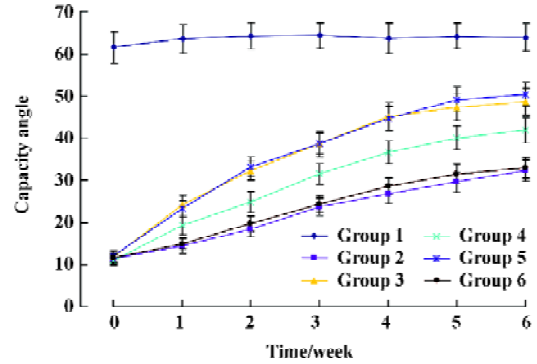


Figure 2. Inclined angle board scores in all groups. The maximum angles at which rats can support their weight are significantly higher in the groups 3 (resveratrol) and 5 (MP+resveratrol) than group 4 (MP) ($P<0.05$). $n=6$. Mean \pm SEM. Group 1: Laminectomy. Group 2: Laminectomy+SCI; Group 6: Laminectomy+SCI+ethanol.

Inclined plane score Trauma produced a highly significant decrease in angle score, which then gradually recovered over a period of 6 weeks in the rats treated with resveratrol, MP and MP+resveratrol ($P<0.05$) (Figure 2). Groups 3 and 5 revealed significantly more improvement rates for the capacity on the inclined angle board than group 4 ($P<0.05$).

Histopathological assessment Spinal cord sections obtained from sham-surgery animals were normal. The epicenter of the injured spinal cord obtained from trauma and vehicle groups showed characteristic necrosis, wide demyelination, and cavitation of white matter in the posteromedial

regions of the spinal cord (Figure 3A, 3E). Treatment groups (groups 3,4,5) showed lower cavitation than group 2 and 6 and these groups are correct of white matter in the posteromedial regions of the spinal cord (Figure 3B–3D).

The injured area was selected and calculated as a percentage of the whole spinal cord area (Figure 4). Lesion area in the spinal cord in group 2 and 6 were calculated as 27% and 26.6%, respectively. Treatment with resveratrol, MP and resveratrol+MP significantly reduced the contused areas (19.3%, 20.4%, and 18.8%, respectively) ($P<0.05$). There was no significant difference between the treatment groups

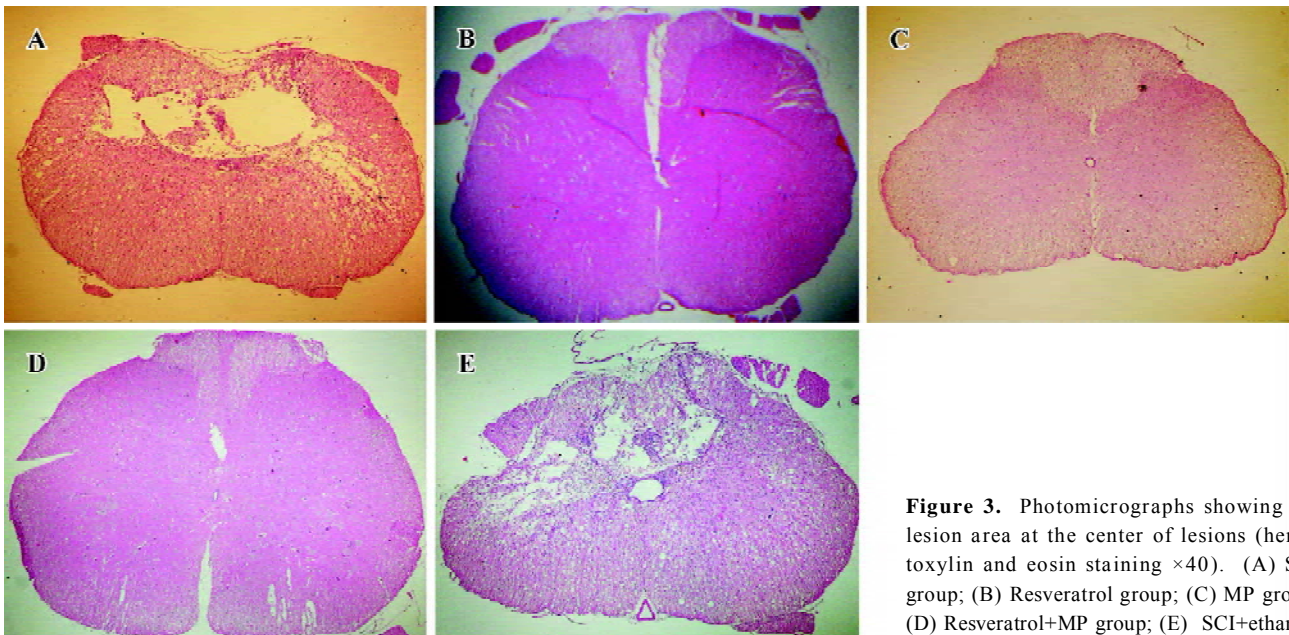


Figure 3. Photomicrographs showing the lesion area at the center of lesions (hematoxylin and eosin staining $\times 40$). (A) SCI group; (B) Resveratrol group; (C) MP group; (D) Resveratrol+MP group; (E) SCI+ethanol.

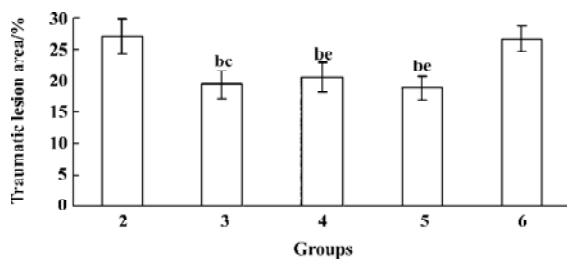


Figure 4. Graphic showing the mean values of lesion area which presented as a percentage of the whole spinal cord area 6 weeks after trauma. Lesion area in the resveratrol (3), methylprednisolone (4) and combined treatment groups (5) are lower than trauma (2) and vehicle groups (6). $n=6$. Mean \pm SEM. ^b $P<0.05$ vs group 2. ^e $P<0.05$ vs group 6.

($P>0.05$).

Biochemical analysis

Lipid peroxidation levels Trauma and vehicle groups were found to produce a significant elevation in lipid peroxidation levels. Groups 3–5 revealed significantly lower MDA levels than groups 2 and 6 ($P<0.05$). However group 3 revealed significantly lower MDA levels than group 4 ($P<0.05$), group 5 showed significantly lower MDA levels when compared to groups 3 and 4 ($P<0.05$) (Figure 5).

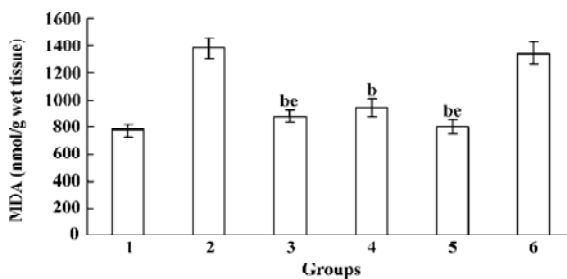


Figure 5. Graphic showing the mean values of MDA levels demonstrated at the 24 h postinjury. Combined treatment with resveratrol and methylprednisolone (group 5) revealed significantly lower MDA levels than resveratrol (3) and methylprednisolone (4) treatment groups ($P<0.05$). $n=6$. Mean \pm SEM. Group 1: Laminectomy. Group 2: Laminectomy+SCI; Group 6: Laminectomy+SCI+ethanol. ^b $P<0.05$ vs group 6. ^e $P<0.05$ vs group 4.

Glutathione levels GSH levels were estimated in both control, trauma, vehicle and treatment groups (Figure 6). Levels of reduced glutathione in trauma and vehicle groups were significantly lower than the control group ($P<0.05$). Groups 3–5 revealed significantly higher GSH levels than groups 2 and 6 ($P<0.05$). Groups 3 and 5 revealed significantly higher GSH levels when compared to group 4 ($P<$

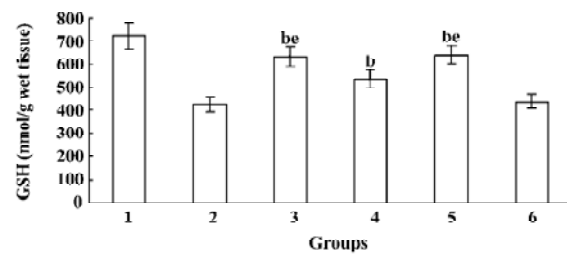


Figure 6. Effect of resveratrol (3), methylprednisolone (4) and combined treatment (5) with both agents on GSH levels 24 h after trauma (2). Resveratrol and combined treatment groups revealed significantly higher GSH levels than methylprednisolone treatment group ($P<0.05$). $n=6$. Mean \pm SEM. Group 1: Laminectomy alone. ^b $P<0.05$ vs group 6. ^e $P<0.05$ vs group 4.

0.05). There was no significant difference between groups 3 and 5 ($P>0.05$).

Nitrite/nitrate levels Trauma caused significant elevation in NO levels ($P<0.05$). Treatment with resveratrol, MP and resveratrol+MP significantly reduced NO levels ($P<0.05$). Combined treatment with resveratrol and MP caused significantly lower NO levels than resveratrol and MP treatment groups ($P<0.05$). Similar to the combined treatment group, the resveratrol treatment group revealed lower NO levels than the MP group ($P<0.05$) (Figure 7).

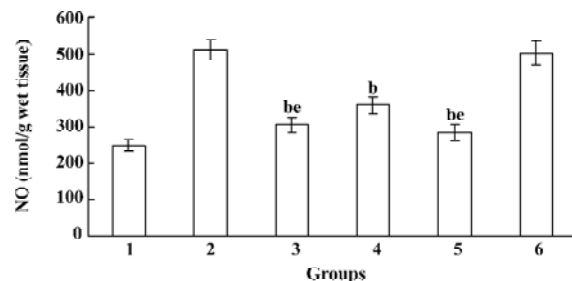


Figure 7. Graphic showing the mean values of NO levels. Combined treatment group (group 5) revealed significantly lower NO levels than resveratrol (3) and methylprednisolone (4) treatment groups ($P<0.05$). $n=6$. Mean \pm SEM. Group 1: Laminectomy. Group 2: Laminectomy+SCI; Group 6: Laminectomy+SCI+ethanol. ^b $P<0.05$ vs group 6. ^e $P<0.05$ vs group 4.

Xanthine oxidase (XO) levels XO levels significantly elevated in the trauma and vehicle groups when compared to the control group ($P<0.05$). Treatment with MP, resveratrol or combined treatment with MP and resveratrol significantly decreased the XO levels ($P<0.05$). When all treatment groups were compared to each other, groups 3 and 5 revealed significantly lower XO levels than group 4 ($P<0.05$). There was

no significant difference between group 3 and 5 ($P>0.05$) (Figure 8).

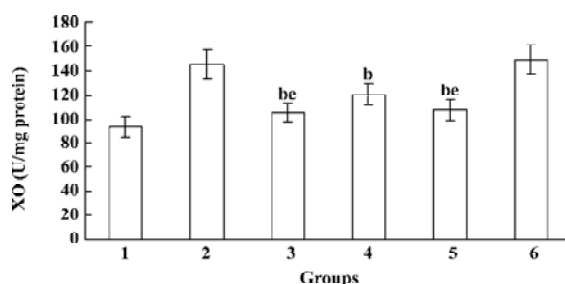


Figure 8. Graphic showing the mean values of XO activity in all groups. Note the resveratrol (3) and combined treatment groups (5) revealed significantly lower XO levels than methylprednisolone (4) treatment group. (1)Laminectomy. (2) Laminectomy+SCI; (6) Laminectomy+SCI+ethanol. $n=6$. Mean \pm SEM. ^b $P<0.05$ vs group 1. ^c $P<0.05$ vs group 4.

Discussion

In the present study, we have demonstrated neuroprotective effects of resveratrol after SCI. Our study confirmed a previous study^[36] that resveratrol reduced lipid peroxidation and showed that resveratrol had a beneficial effect on long term neurological and histopathological outcome after SCI.

Traumatic spinal cord injury proceeds through a series of sequential events, beginning with primary injury and followed by secondary injury. Tissue repair, and some degree of neurological recovery after injury depend on the severity of primary injury. Primary mechanical injury may cause neuronal tissue damage and loss of axons, rupture of arterioles and venules causing hemorrhage and blockage of axoplasmic transport. The pathological processes involved in secondary injury include free radical generation, intracellular influx of calcium, ischaemia and edema^[17,37,38].

Previous studies showed that high-dose MP had a neuroprotective effect immediately after SCI. The reduction of lipid peroxidation has been postulated to be the major neuroprotective mechanism of MP^[14,39,40]. It suppresses the breakdown of membranes by inhibiting lipid peroxidation and hydrolysis at the site of injury^[5,41]. Young recommended that all experimental SCI studies should be compared with treatment agonist MP^[42]. So, we used MP in this study to compare against resveratrol.

Reactive oxygen species (ROS) consist of oxygen free radicals and associated entities that include superoxide free radicals, hydrogen peroxide, singlet oxygen, nitric oxide (NO), and peroxy nitrite. The production of ROS can lead to cell

injury through cell membrane lipid destruction and can diffuse intracellularly and cause mitochondrial enzyme damage and cleavage of DNA^[43,44]. Recently, resveratrol was found to be a highly potent antioxidant that could inhibit free radical generation in the brain, spinal cord, heart, kidney, liver, red cell membrane, and so on^[19,36,44-49]. It has been shown that it inhibits lipid peroxidation^[50], and prevents apoptotic cell death induced by oxidative stress^[51,52]. It has been postulated that resveratrol could suppress mitochondria-induced production of ROS in rat brain^[53], protect DNA from oxidative damage in stroke-prone hypertensive rats^[54], and could inhibit neuronal loss after ischemia/reperfusion injury in gerbils^[44]. Direct neuroprotective effect of resveratrol against oxidative stress has been demonstrated in PC12 cells^[55]. After SCI, blood flow in the spinal cord is reduced, microcirculation is disturbed and microvascular permeability increases, which leads to spinal cord edema^[26]. Kaplan *et al* showed that prophylactic use of resveratrol reduced neurologic injury and provided clinical improvement by attenuating the inflammatory milieu in the rabbit spinal cord ischemia/reperfusion model^[56]. Yang *et al* showed that resveratrol reduced spinal cord edema rates by 11.5% and improved the energy metabolism system 48 h after SCI^[36].

It is known that lipid peroxidation products increase soon after injury^[4,57]. Free oxygen radical-mediated lipid peroxidation has been increasingly suggested to be an important factor in posttraumatic neuronal degeneration. MDA is a main breakdown product of LP in the CNS and is formed from the breakdown of polyunsaturated fatty acids, serving as a convenient index for determining the extent of lipid peroxidation. In the present study, tissue lipid peroxidation was evaluated by measuring the thiobarbituric acid reactive substances. Recent studies showed that MDA levels in the injured spinal cord had similar values within 24 h^[38]. So, we assessed MDA levels of all groups at the 24 h post-injury. Our study showed that resveratrol treatment was more effective than MP treatment and combined treatment with resveratrol and MP had an additional protective effect on lipid peroxidation levels. The effect of MP and resveratrol on lipid peroxidation is on a different route. MP, a glucocorticoid with potent anti-inflammatory properties, induces synthesis and the release of anti-inflammatory peptides. This activity plays a major role in its neuroprotective effect and requires receptor activation^[58]. Resveratrol is known as a free radical scavenger. Additional neuroprotection on lipid peroxidation with a combined treatment may be explained by the synergistic or additive effect of resveratrol and MP in the acute phase of injury.

The potential harmful effect of oxidative stress is con-

trolled by cellular antioxidant defense mechanisms including enzymatic defense systems and non-enzymatic defense systems such as reduced glutathione (GSH). Glutathione is an endogenous antioxidant found in all animal cells. It reacts with the free radicals and can protect cells from singlet oxygen, hydroxide radical, and superoxide radical damage. Decreased levels of reduced glutathione has been reported after excessive generation of free radicals and described as a result of compensatory mechanism to combat increased oxidative stress^[6,59]. In the present study a decreased level of glutathione was seen after SCI. This result may be secondary to raised MDA levels. All the treatment groups were found to have significantly elevated GSH levels. Similar to lipid peroxidation, resveratrol treatment resulted in higher GSH levels than MP treatment, but combined treatment with both agents did not reveal additional neuroprotection.

Oxygen free radicals can be generated by a variety of sources at the cellular level. An important source of oxygen free radicals is known to be xanthine oxidase (XO), which can be formed from xanthine dehydrogenase (XD) either reversibly (via oxidation or blockage of its thiol groups) or irreversibly (via limited proteolysis) in pathological conditions^[60]. In a normal tissue, XD, which is the native form of the enzyme, catalyzes the conversion of hypoxanthine to xanthine and uric acid through the utilization of NAD^+ as its electron acceptor. Indeed, this reaction does not lead to the production of oxygen free radicals or the generation of hydrogen peroxide (H_2O_2). However, XO is also able to catalyze the reduction of oxygen in the pathological states leading to the formation of superoxide (O_2^-) and H_2O_2 where the reaction is considered to play a crucial role in the proposed mechanism of oxidative injury^[60,61].

Nitric oxide (NO) is a free radical gas molecule that is produced from *L*-arginine by the catalytic action of nitric oxide synthases (eNOS, iNOS, and nNOS)^[62]. In physiological levels, NO participates in a variety of physiological processes consisting of neurotransmission and regulation of the blood vessel wall^[63]. But increased NO, especially associated with oxidative stress, is a harmful condition for tissue. In the present study, both GSH, XO, and NO levels have been used in order to show the severity of spinal cord injury and the effectiveness of pharmacological agents on oxidative stress. It is shown that resveratrol is more effective on both GSH, XO, and NO levels than MP. Combined treatment revealed more neuroprotective effects only for NO levels.

The neurological deficits following spinal cord trauma may increase during the first hours up to the first week following injury. Behavioral tests are important tools to assess the outcome of experimental spinal cord injuries, including

spontaneous functional improvement over time, and the effects of different treatments. Many experimental and clinical studies have focused on secondary injury mechanisms in an effort to improve neurological outcome following spinal cord injury. A reliable test protocol suitable for the injury model used is essential to evaluate functional recovery after spinal cord injury^[27,28,64,65]. The inclined plane is a test known to be sensitive and reliable in evaluating different degrees of spinal cord injury. This test has been validated for rats with compression injuries as well as contusive injuries^[27,28]. A significant slower recovery was observed in all of the injured rats treated with MP, resveratrol or combined treatment for motor function score and inclined angle board capacity. When each group was evaluated by itself, statistically significant differences were found between the first and the sixth weeks for the all groups. However, significant differences in the amounts of recovery rates were found among them. At the end of observation it can be stated that the effect of resveratrol on neurological recovery is better than MP, and the combined treatment of both drugs did not contribute to an increased rate of recovery.

Yang *et al* demonstrated that both resveratrol and MP had a protective effect on axons, neurons, myelin and subcellular organelles^[36]. But their experimental design comprised the acute phase of the SCI (48 h maximum). The present experimental results suggest that single dose of 100 mg/kg resveratrol administration could effectively reduce the lesion area after SCI. When resveratrol treatment was compared to MP treatment, at the end of the 6 weeks, resveratrol did not have a more remarkable protective effect on the lesion area. Combined treatment with resveratrol and MP did not provide an additional effect on the lesion area. From our findings, we can propose that resveratrol strongly improves the histopathological outcome following spinal cord injury. Yang *et al* used single doses of 50 mg/kg and 100 mg/kg resveratrol in their study where they suggested that resveratrol had a stronger effect in improving the energy metabolism system and inhibiting the LP than MP at a dose of 100 mg/kg. In our study we used a 100 mg/kg single dose of resveratrol and a 30 mg/kg single dose of MP^[38]. Our results showed that treatment with resveratrol revealed better results for both MDA, GSH, NO, and XO levels than MP treatment in the acute stage of experiment. And also that resveratrol treatment revealed better results for neurobehavioral recovery in the chronic stage of the experiment. The interesting finding in this study is that, in spite of better biochemical results in the resveratrol treatment group in the acute stage of the study, all the treatment groups revealed similar histopathological recovery at the chronic stage. It

could be stated that combined treatment with both drugs doesn't give significantly better results than separate using of them for the chronic stage of SCI.

In conclusion, resveratrol treatment is more effective than MP treatment for the prevention of lipid peroxidation after spinal cord injury in the acute stage of SCI. The anti-oxidative effect of MP and resveratrol is by different routes. These different anti-oxidative mechanisms provide additional protection in the acute stage. Although there was better neurobehavioral recovery in the resveratrol treatment group, each agent caused similar histopathological recovery in the chronic stage. So, we can claim that resveratrol is an agent at least as effective as MP on secondary damage after SCI. Although they prevent secondary damage through different mechanisms, combined use does not provide extra protection in the chronic stage of SCI.

References

- Dolan ES, Tator CH. The treatment of hypotension due to acute experimental spinal cord compression injury. *Surg Neurol* 1980; 13: 380–4.
- Ducker TB, Salzman M, Perot PL Jr, Ballantine D. Experimental spinal cord trauma I: correlation of blood flow, tissue oxygen and neurologic status in the dog. *Surg Neurol* 1978; 10: 60–3.
- Hall ED. Lipid peroxidants in acute central nervous system injury. *Ann Emerg Med* 1993; 22: 1022–7.
- Anderson DK, Hall ED. Pathophysiology of spinal cord trauma. *Ann Emerg Med* 1993; 22: 987–92.
- Hall ED. The neuroprotective pharmacology of methylprednisolone. *J Neurosurg* 1992; 76: 13–22.
- Shi MM, Kugelmann A, Iwamoto T, Tian L, Forman HJ. Quinone induced oxidative stress elevates glutathione and induces glutamylcysteine synthetase activity in rat lung epithelial L2 cells. *J Biol Chem* 1994; 269: 26512–7.
- Tator CH, Fehlings MG. Review of the secondary injury theory of acute spinal cord trauma with emphasis on vascular mechanisms. *J Neurosurg* 1991; 75: 15–26.
- Young W. Secondary injury mechanisms in acute spinal cord injury. *J Emerg Med* 1993; 11: 13–22.
- Allen AR. Remarks on the histopathological changes in the spinal cord due to impact. An experimental study. *J Nerv Ment Dis* 1914; 41: 141–7.
- Collins WF. A review and update of experimental and clinical studies of spinal cord injury. *Paraplegia* 1983; 21: 204–19.
- Nash HH, Borke RC, Anders JJ. Ensheathing cells and methylprednisolone promote axonal regeneration and functional recovery in the lesioned adult rat spinal cord. *J Neurosci* 2002; 22: 7111–20.
- Oudega M, Vargas CG, Weber AB, Kleitman N, Bunge MB. Long-term effects of methylprednisolone following transection of the adult rat spinal cord. *Eur J Neurosci* 1999; 11: 2453–64.
- Ji B, Li M, Budel S, Pepinsky RB, Walus L, Engber TM, *et al*. Effect of combined treatment with methylprednisolone and soluble Nogo-66 receptor after rat spinal cord injury. *Eur J Neurosci* 2005; 22: 587–94.
- Anderson DK, Saunders RS, Demediuk P, Dugan LL, Braugher JM, Hall ED, *et al*. Lipid hydrolysis and peroxidation in injured spinal cord: partial protection with methylprednisolone or vitamin E and selenium. *Cent Nerv Syst Trauma* 1985; 2: 257–67.
- Soleas GJ, Diamandis EP, Goldberg DM. Wine as a biological fluid: history, production, and role in disease prevention. *J Clin Lab Anal* 1997; 11: 287–313.
- Daniel O, Meier MS, Schlatter J, Frischhnecht P. Selected phenolic compounds in cultivated plants: ecologic functions, health implications, and modulation by pesticides. *Environ Health Perspect* 1999; 107: 109–14.
- Sobolev VS, Cole RJ. *Trans*-resveratrol content in commercial peanuts and peanut products. *J Agric Food Chem* 1999; 47: 1435–9.
- Inoue H, Umesono K, Nishimori T, Hirata Y, Tanabe T. Glucocorticoid-mediated suppression of the promoter activity of the cyclooxygenase-2 gene is modulated by expression of its receptor in vascular endothelial cells. *Biophys Biophys Res Commun* 1999; 254: 292–8.
- Sinha K, Chaudray G, Gupta YK. Protective effect of resveratrol against oxidative stress in middle cerebral artery. *Life Sci* 2002; 71: 655–65.
- Inoue H, Tanabe T, Umesono K. Feedback control of cyclooxygenase-2 expression through PPAR γ . *J Biol Chem* 2000; 275: 28028–32.
- Huang SS, Tsai MC, Chih CL, Hung LM, Tsai SK. Resveratrol reduction of infarct size in Long-Evans rats subjected to focal cerebral ischemia. *Life Sci* 2001; 69: 1057–65.
- Bloomfield Rubins H, Davenport J, Babikian V, Brass LM, Collins D, Wexler L, *et al*. VA-HIT Study Group. Reduction in stroke with gemfibrozil in men with coronary heart disease and low HDL cholesterol: The Veterans Affairs HDL Intervention Trial (VA-HIT). *Circulation* 2001; 103: 2828–33.
- Frémont L. Biological effects of resveratrol. *Life Sci* 2000; 66: 663–73.
- Kimura Y, Okuda H, Arichi S. Effects of stilbenes on arachidonate metabolism in leukocytes. *Biochim Biophys Acta* 1985; 834: 275–8.
- Allen AR. Surgery of experimental lesion of spinal cord equivalent to crush injury of fracture dislocation of spinal column. A preliminary report. *JAMA* 1911; 57: 878–80.
- Farooque M, Isaksson J, Jackson D, Olsson Y. Clomethiazole improves hind limb function and reduces neuronal damage after severe spinal cord injury in rat. *Acta Neuropathol* 1999; 98: 22–30.
- Gale K, Kerasidis H, Wrathall JR. Spinal cord contusions in the rat: behavioral analysis of functional neurologic impairment. *Exp Neurol* 1985; 88: 123–34.
- Rivlin AS, Tator CH. Objective clinical assessment of motor function after experimental spinal cord injury in the rat. *J Neurosurg* 1977; 47: 577–81.
- Huang L, Mehta MP, Nanda A, Zhang JH. The role of multiple hyperbaric oxygenation in expanding therapeutic windows after acute spinal cord injury in rats. *J Neurosurg* 2003; 99: 198–205.
- Mihara M, Uchiyama M. Determination of malonaldehyde precursor in tissues by thiobarbituric acid test. *Anal Biochem* 1978; 86: 271–8.

- 31 Elman GL. Tissue sulphhydryl groups. *Arch Biochem Biophys* 1959; 82: 70–7.
- 32 Jungersten L, Edlund A, Petersson AS, Wennmalm A. Plasma nitrate as an index of nitric oxide formation in man: analyses of kinetics and confounding factors. *Clin Physiol* 1996; 16: 369–79.
- 33 Zeballos GA, Bernstein RD, Thompson CI, Forfia PR, Seyedi N, Shen W, *et al*. Pharmacodynamics of plasma nitrate/nitrite as an indication of nitric oxide formation in conscious dogs. *Circulation* 1995; 91: 2982–8.
- 34 Ozbek E, Turkoz Y, Gokdeniz R, Davarci M, Ozugurlu F. Increased nitric oxide production in the spermatic vein of patients with varicocele. *Eur Urol* 2000; 37: 172–5.
- 35 Prajda N, Weber G. Malignant transformation-linked imbalance: decreased xanthine oxidase activity in hepatomas. *FEBS Lett* 1975; 59: 245–9.
- 36 Yang YB, Piao YJ. Effects of resveratrol on secondary damages after acute spinal cord injury in rats. *Acta Pharmacol Sin* 2003; 24: 703–10.
- 37 Koc RK, Akdemir H, Kurtsoy A, Pasaoglu H, Kavuncu I, Pasaoglu A, *et al*. Lipid peroxidation in experimental spinal cord injury. Comparison of treatment with *Ginkgo biloba*, TRH and methylprednisolone. *Res Exp Med (Berl)* 1995; 2: 117–23.
- 38 Cayli SR, Kocak A, Yilmaz U, Tekiner A, Erbil M, Ozturk C, *et al*. Effect of combined treatment with melatonin and methylprednisolone on neurological recovery after experimental spinal cord injury. *Eur Spine J* 2004; 13: 724–32.
- 39 Braughler JM, Hall ED. Correlation of methylprednisolone levels in cat spinal cord with its effects on (Na⁺K)-ATPase, lipid peroxidation, and alpha motor neuron function. *J Neurosurg* 1982; 56: 838–44.
- 40 Braughler JM, Hall ED. Current application of “high dose” steroid therapy for CNS injury. A pharmacological perspective. *J Neurosurg* 1985; 62: 806–10.
- 41 Young W, Flamm ES. Effects of high-dose corticosteroid therapy on blood flow, evoked potentials and extracellular calcium in experimental spinal cord injury. *J Neurosurg* 1982; 57: 667–73.
- 42 Young W, Bracken MB. The second national acute spinal cord injury study. *J Neurotrauma* 1992; 9 (Suppl 1): 397–405.
- 43 Kristal BS, Koopmans SJ, Jackson CT, Ikeno Y, Park BS, Yu BP. Oxidant-mediated repression of the mitochondrial transcription in diabetic rats. *Free Radic Biol Med* 1997; 22: 813–22.
- 44 Wang Q, Xu J, Rottinghaus GE, Simonyi A, Lubahn D, Sun GY, *et al*. Resveratrol protects against global cerebral ischemic injury in gerbils. *Brain Res* 2002; 958: 439–47.
- 45 Cai YJ, Fang JG, Ma LP, Yang L, Liu ZL. Inhibition of free radical-induced peroxidation of rat liver microsomes by resveratrol and its analogues. *Biochim Biophys Acta* 2003; 1637: 31–8.
- 46 Caimi G, Carollo C, Lo Presti R. Chronic renal failure: oxidative stress, endothelial dysfunction and wine. *Clin Nephrol* 2004; 62: 331–5.
- 47 Dernek S, Ikizler M, Erkasap N, Ergun B, Koken T, Yilmaz K. Cardioprotection with resveratrol pretreatment: improved beneficial affects over Standard treatment in rat hearts after global ischemia. *Scand Cardiovasc J* 2004; 38: 245–54.
- 48 Kiziltepe U, Turan NN, Han U, Ulus AT, Akar F. Resveratrol, a red wine polyphenol, protects spinal cord from ischemia-reperfusion injury. *J Vasc Surg* 2004; 40: 138–45.
- 49 Olas B, Nowak P, Wachowicz B. Resveratrol protects against peroxynitrite-induced thiol oxidation in blood platelets. *Cell Mol Biol Lett* 2004; 9: 577–87.
- 50 Tadolini B, Juliano C, Piu L, Franconi F, Cabrini L. Resveratrol inhibition of lipid peroxidation. *Free Radic Res* 2000; 33: 104–14.
- 51 Chanvitayapongs S, Draczynska-Lusiak B, Sun AY. Amelioration of oxidative stress by antioxidants and resveratrol in PC12 cells. *Neuroreport* 1997; 8: 1499–502.
- 52 Draczynska-Lusiak B, Chen YM, Sun AY. Oxidized lipoprotein, activate NF- κ B binding activity and apoptosis in PC12 cells. *Neuroreport* 1998; 9: 527–32.
- 53 Zini R, Morin C, Berteli A, Berteli AA, Tillement JP. Effects of resveratrol on the rat brain respiratory chain. *Drugs Exp Clin Res* 1999; 25: 87–97.
- 54 Mizutani K, Ikeda K, Kawai Y, Yamori Y. Protective effect of resveratrol on oxidative damage in male and female stroke-prone spontaneously hypertensive rats. *Clin Exp Pharmacol Physiol* 2001; 28: 55–9.
- 55 Virgili M, Contestabile A. Partial neuroprotection of *in vivo* excitotoxic brain damage by chronic administration of the red wine antioxidant agents, *trans*-resveratrol in rats. *Neurosci Lett* 2000; 281: 123–6.
- 56 Kaplan S, Bisleri G, Morgan JA, Cheema FH, Oz MC. Resveratrol, a natural red wine polyphenol, reduces ischemia-reperfusion induced spinal cord injury. *Ann Thorac Surg* 2005; 80: 2242–9.
- 57 Barut S, Canbolat A, Bilge T, Aydin Y, Cokneseli B, Kaya U. Lipid peroxidation in experimental spinal cord injury: time–level relationship. *Neurosurg Rev* 1993; 16: 53–9.
- 58 Constantini S, Young W. The effects of methylprednisolone and the ganglioside GM1 on acute spinal cord injury in rats. *J Neurosurg* 1994; 80: 97–111.
- 59 Sinha K, Deogonakar M, Jagannathan NR, Gupta YK. Effect of melatonin on ischemia reperfusion injury induced by middle cerebral artery occlusion in rats. *Eur J Pharmacol* 2001; 428: 185–92.
- 60 Hile R, Nishino T. Flavoprotein structure and mechanism. 4. Xanthine oxidase and xanthine dehydrogenase. *FASEB J* 1995; 9: 995–1003.
- 61 Corte ED, Stirpe F. The regulation of rat liver xanthine oxidase. Involvement of thiol groups in the conversion of the enzyme activity from dehydrogenase (type D) into oxidase (type O) and purification of the enzyme. *Biochem J* 1972; 126: 739–45.
- 62 Moncada S, Higgs A. The L-arginine-nitric oxide pathway. *N Engl J Med* 1993; 329: 2002–12.
- 63 Peunova N, Enikolopov G. Amplification of calcium-induced gene transcription by nitric oxide in neuronal cells. *Nature* 1993; 364: 450–3.
- 64 Goldberger ME, Bregman BS, Vierck Jr CJ, Brown M. Criteria for assessing recovery of function after spinal cord injury: Behavioral methods. *Exp Neurol* 1990; 107: 113–7.
- 65 Von Euler M, Akesson E, Samuelsson EB, Seiger A, Sundström E. Motor performance score: a new algorithm for accurate behavioral testing of spinal cord injury in rats. *Exp Neurol* 1996; 137: 242–5.